

PART II – NEUROLOGICAL DISORDERS

CHAPTER 18
INHERITED NEUROLOGICAL DISORDERS

Dr William P. Howlett
2012

Kilimanjaro Christian Medical Centre,
Moshi,
Kilimanjaro,
Tanzania

BRIC 2012



University of Bergen
PO Box 7800
NO-5020 Bergen
Norway

NEUROLOGY IN AFRICA

William Howlett

Illustrations: Ellinor Moldeklev Hoff, Department of Photos and Drawings, UiB

Cover: Tor Vegard Tobiassen

Layout: Christian Bakke, Division of Communication, University of Bergen

Printed by Bodoni, Bergen, Norway 

Copyright © 2012 William Howlett

NEUROLOGY IN AFRICA is freely available to download at

Bergen Open Research Archive (<https://bora.uib.no>)

www.uib.no/cih/en/resources/neurology-in-africa

ISBN 978-82-7453-085-0

Notice/Disclaimer

This publication is intended to give accurate information with regard to the subject matter covered. However medical knowledge is constantly changing and information may alter. It is the responsibility of the practitioner to determine the best treatment for the patient and readers are therefore obliged to check and verify information contained within the book. This recommendation is most important with regard to drugs used, their dose, route and duration of administration, indications and contraindications and side effects. The author and the publisher waive any and all liability for damages, injury or death to persons or property incurred, directly or indirectly by this publication.

CONTENTS

INHERITED NEUROLOGICAL DISORDERS	399
NEUROFIBROMATOSIS TYPE 1	399
NEUROFIBROMATOSIS TYPE 2	402
TUBEROUS SCLEROSIS	403
STURGE WEBER SYNDROME	403
SPINOCEREBELLAR DISORDERS	404
FRIEDREICH'S ATAXIA	404
INHERITED NEUROPATHIES	405
HUNTINGTON'S DISEASE (HD)	405
OTHER HEREDITARY NEUROLOGICAL DISORDERS	406
HEREDITARY SPASTIC PARAPARESIS (HSP)	406
WILSON'S DISEASE	407

CHAPTER 18

INHERITED NEUROLOGICAL DISORDERS

Inherited neurological disorders are generally relatively uncommon (Table 18.1). Their frequency in Africa is largely unknown. Inheritance follows the basic Mendelian laws for autosomal dominant, autosomal recessive and X-linked recessive inheritance. An example of an autosomal dominant disorder is neurofibromatosis and of an autosomal recessive disorder is Friedreich's ataxia. Duchenne's and Becker's muscular dystrophy (Chapter 13) are both X-linked disorders. Huntington's disease is an example of an autosomal dominant and a trinucleotide repeat disorder. A positive family history can usually be elicited in the autosomal dominant and X-linked disorders, underlining the importance of the family history. The aim of this chapter is to review the more commonly encountered hereditary neurological disorders. The student should aim to recognize and be familiar with the main ones.

Table 18.1 Characteristics of the main inherited neurological disorders

Disorder	Genetics	Age of onset	Frequency*	Main clinical features
Neurofibromatosis type 1	autosomal dominant	children & adults	1/4000	neurofibroma on nerves, café-au-lait spots >5, axillary freckling
Neurofibromatosis type 2	autosomal dominant	adults	1/50,000	deafness, bilateral acoustic neuromas
Tuberous Sclerosis	autosomal dominant	children & young adults	1/15,000	epilepsy, adenoma sebaceum on face, hamartoma
Friedreich's ataxia	autosomal recessive	teens	1/50,000	cerebellar signs, progressive gait ataxia, upper motor neurone signs, absent ankle jerks
Charcot-Marie-Tooth disease	autosomal dominant	young adults	1/3,000	peripheral neuropathy, marked lower limb distal wasting, high arched feet (pes cavus)
Huntington's disease	autosomal dominant	middle aged adults	1/10,000	choreaform movements, progressive dementia, psychiatric symptoms

* frequencies based on studies in high income countries

NEUROFIBROMATOSIS TYPE 1

Neurofibromatosis type 1 is an autosomal dominant disorder with an age-dependent penetrance caused by a defect in the *NF1* gene (neurofibromin) on chromosome 17q occurring with a frequency of about 1 in 4-5,000 (Table 18.1). Its frequency in Africa is likely to be similar. About 30-50% of cases are the result of new mutations. Clinically, it is characterised

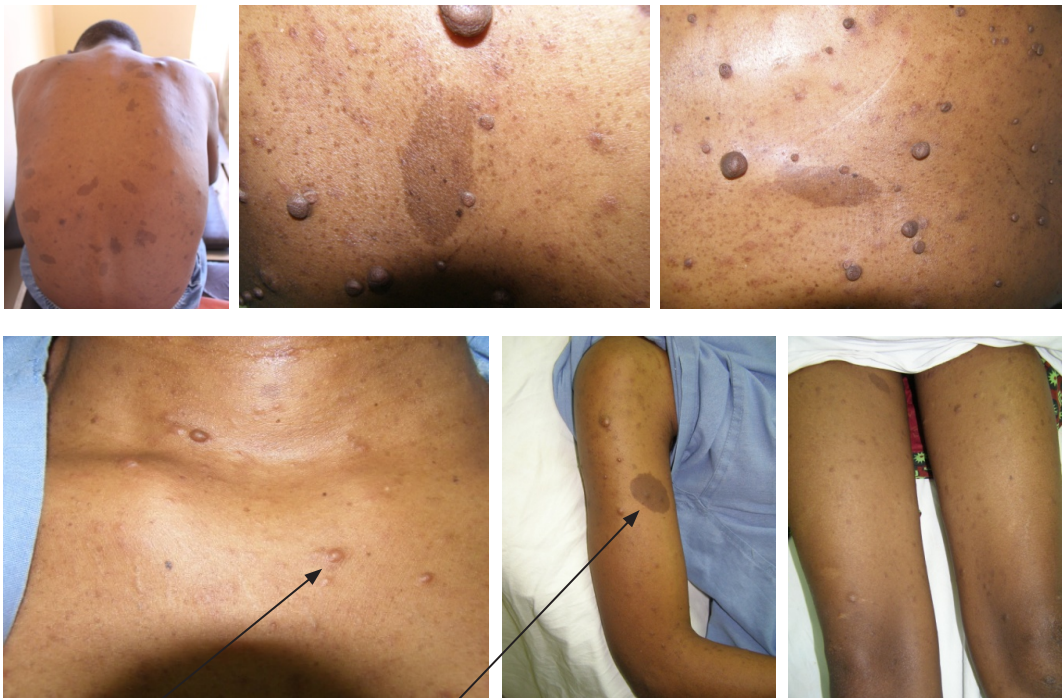CHAPTER 18 INHERITED NEUROLOGICAL DISORDERS

by neurofibromata lying on peripheral nerves, multiple cutaneous fibromas, and more than 5 hyperpigmented or café-au-lait (CAL) spots on the trunk (Fig. 18.1); see NIH clinical criteria and main clinical features NF1 (Table 18.2). The clinical picture can vary from very few to very many and distinctive skin lesions. Other clinical findings include axillary, neck and groin freckling, Lisch nodules on the iris and sometimes a scoliosis. Patients with type 1 may develop paraplegia secondary to an expanding intra axial neurofibroma arising from a nerve root pressing on the spinal cord (Fig. 18.1). They are also at risk for large deforming plexiform neuromas (Fig. 18.1), sarcomas, brain gliomas and pheochromocytoma.

Table 18.2 Diagnostic criteria for NF1

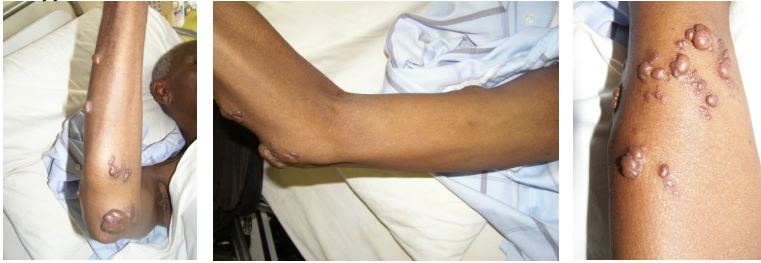Criteria: a diagnosis of NF type 1 is met if any two or more of the following is met.
6 or more CAL* spots 1.5 cm or larger in post pubertal patients 0.5 cm or larger in prepubertal patients
2 or more neurofibromata of any type or 1 or more plexiform neurofibroma
freckling in axilla, neck or groin
optic glioma
2 or more Lisch nodules
a distinctive bone lesion dysplasia of the sphenoid bone dysplasia or thinning of long bone cortex (tibia)
first degree relative, independently diagnosed with NF1

*Café-au-lait



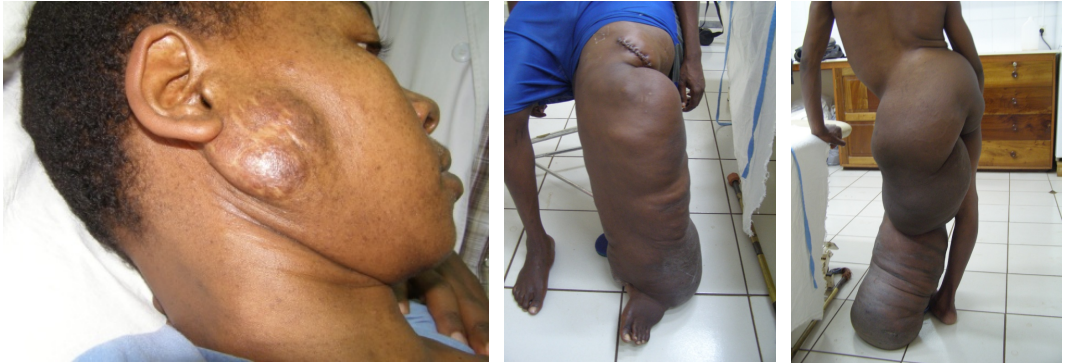Multiple neurofibromata & cafe au lait spots

NF type 1 variant



Segmental neurofibromata localised to dermatomes of right arm

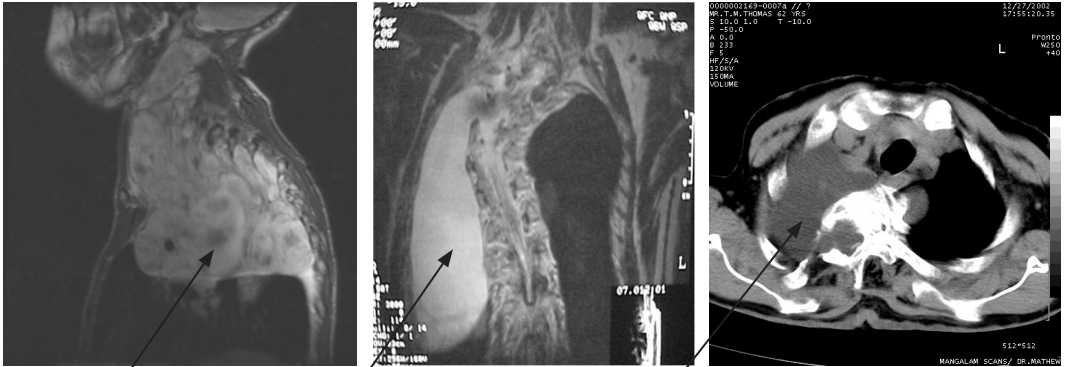
Plexiform neurofibroma



Involving the face

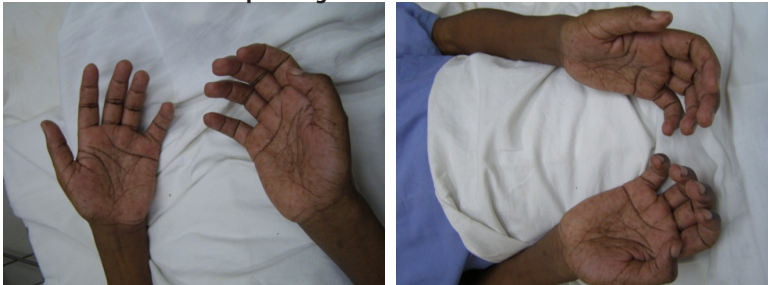Gigantic plexiform neurofibroma of lower back & leg

CT chest



Giant plexiform neurofibroma involving upper mediastinum & right side of chest

Neurofibroma in NF1 compressing cervical cord & nerve roots



Clawing, wasting & weakness of hands

Figure 18.1 Clinical features NF type 1

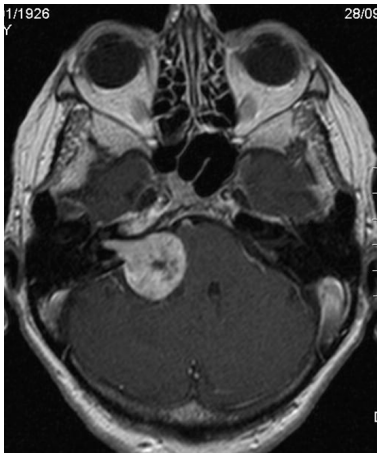
NEUROFIBROMATOSIS TYPE 2

Neurofibromatosis type 2 is a much rarer autosomal dominant disorder affecting about 1 in 50,000 due to a defect in the *NF2* gene (merlin) on chromosome 22. It is characterised by few skin manifestations and the development of intracranial tumours, acoustic neuromas (vestibular Schwannoma) (Fig. 18.2) and meningiomas; see diagnostic criteria (Table 18.3). Deafness due to an acoustic neuroma involving the eighth cranial nerve is the main clinical presentation of type 2. This is usually accompanied by tinnitus, vertigo, ataxia, facial numbness and weakness. The clinical features at presentation are usually unilateral although the acoustic neuromas are commonly bilateral on neuroimaging. The diagnosis is confirmed by neuroimaging of the brain, usually MRI (Fig. 18.2). Management is either conservative by observation only or with deep X-ray therapy (DXT), or surgery for the tumours where possible. Genetic counselling is a very important part of management.

Table 18.3 Diagnostic criteria for NF2

Criteria: a diagnosis of NF2 is made if one of the following is met.
bilateral vestibular Schwannoma, (either histologically or by MRI with contrast)
a parent, sibling or child with NF2 and either a unilateral vestibular Schwannoma or 2 or more of meningioma, glioma, Schwannoma, posterior sub capsular lenticular opacities, cerebral calcifications
multiple meningiomas (2 or more) and one or more of glioma, Schwannoma, posterior sub capsular lenticular opacities, cerebral calcifications

MRI brain

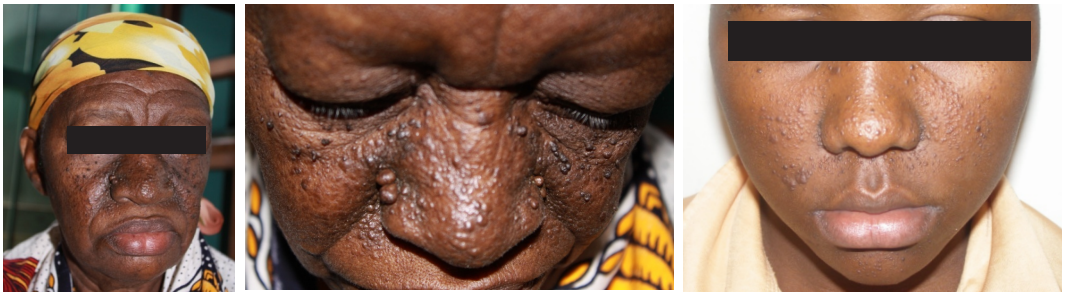

Unilateral Schwannoma (right sided)

Figure 18.2 NF type 2

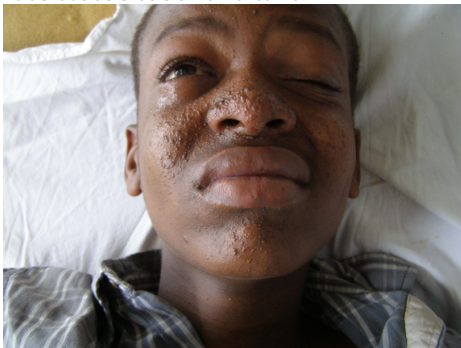TUBEROUS SCLEROSIS

This is an autosomal dominant condition, due to mutations in either *TSC1* on chromosome 9q (hamartin) or *TSC2* on chromosome 16p (tuberin) with a prevalence of 1/15,000. Its frequency is not known in Africa but is most probably the same. About 60% of cases are due to new mutations. The main clinical features are the characteristic facial angiofibromata or adenoma sebaceum lesions on the cheeks and nose (Fig. 18.3), in combination with a history of epilepsy. There may be associated cognitive impairment. Additional skin manifestations include ash leaf hypopigmented macular type patches and the shagreen patch, a 1-10cm patch of orange peel like sub epidermal fibrosis found most often over the lumbar sacral area and subungual fibromas. CT shows a characteristic pattern of paraventricular subependymal calcified nodules or tuberi. Complications include tumours in the brain, hamartoma (Fig. 18.3) and astrocytoma. There are frequently other affected family members, most commonly siblings. Epilepsy may be difficult to control.



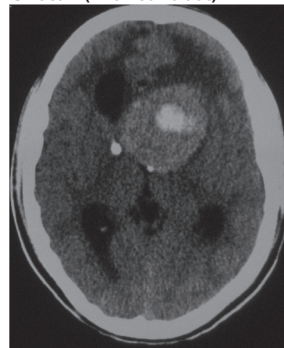
Adenoma sebaceum lesions on the cheeks and nose

Tuberous sclerosis & hamartoma



Adenoma sebaceum & left sided 3rd nerve palsy

CT scan (with contrast)



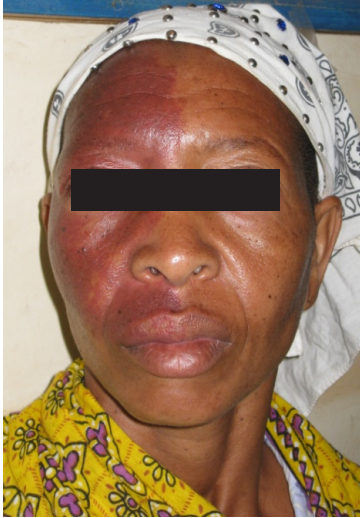Calcified tuberi & hamartoma in the same patient

Figure 18.3 Tuberous sclerosis

STURGE WEBER SYNDROME

This is an uncommon sporadic disorder affecting 1/50,000 in high income countries. It is a neurocutaneous syndrome characterized by a port wine staining affecting one half of the face (Fig. 18.4) usually in a V1 distribution and associated neurological abnormalities. The defining characteristic of the syndrome is an underlying intracranial vascular abnormality in the leptomeninges affecting the cortical regions of the hemispheres. The syndrome includes

seizures, glaucoma, headaches, behavioural problems and stroke like episodes. It has its onset usually in early childhood and is usually progressive. However the clinical course is highly variable and it is important to note that not all children or adults with the characteristic port wine facial staining have the syndrome. Neuroimaging, usually CT confirms the presence of intracerebral calcifications affecting the parietal or occipital lobes on the affected side but they can be generalised. Management is largely symptomatic and supportive.



Port wine staining V1 & 2 distribution

Figure 18.4 Sturge Weber syndrome

SPINOCEREBELLAR DISORDERS

These represent a wide but rare group of disorders with progressive cerebellar degeneration in combination with other neurological findings. Friedrich's ataxia is one of the main early onset ataxias.

FRIEDREICH'S ATAXIA

Friedreich's ataxia is an autosomal recessive condition caused by mutations in the *FRDA* gene (frataxin) on chromosome 9, mostly trinucleotide (GAA) repeat expansions (67–1700). It affects 1/50,000 with its onset usually in young persons under the age of 20 years (average 15.5 years with a range of 2–51 years). The severity of the disease depends on the number of abnormal trinucleotide repeats. The disease is characterized by progressive degeneration of the main cerebellar tracts with involvement of the corticospinal and posterior columns. The main clinical feature is gait ataxia which progressively worsens and may be accompanied by pyramidal findings and peripheral neuropathy (absent ankle jerks). Other less frequent findings include optic atrophy and deafness. There may be a scoliosis, pes cavus, diabetes mellitus and an associated cardiomyopathy as evidenced by widespread T inversion on ECG.

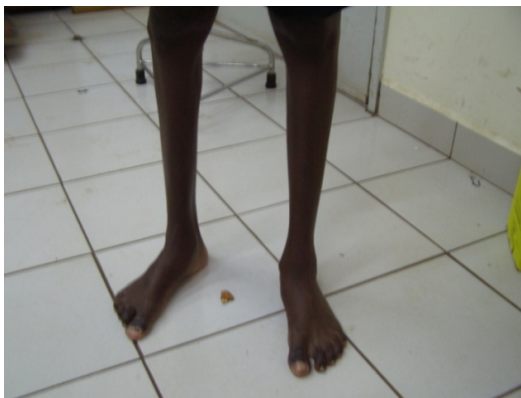There is no treatment for the underlying genetic condition and management is mainly supportive and treatment of complications. The differential diagnosis includes the other hereditary cerebellar ataxias which are mainly the later onset type (>20 yrs) and are mostly

autosomal dominant, mostly due to CAG repeat expansions and often characterized by anticipation. These may have associated spasticity, parkinsonism, neuropathy and retinopathy. A rare form of familial autosomal recessive isolated vitamin E deficiency is clinically very similar to Friedreich's ataxia and responds to high doses of vitamin E orally.

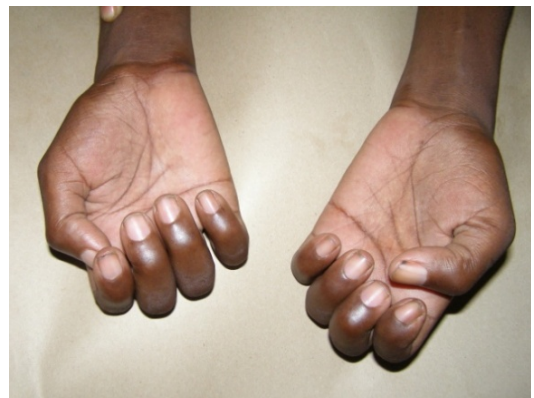INHERITED NEUROPATHIES

These are also called the hereditary motor sensory neuropathies (HMSN). Charcot-Marie-Tooth disease (CMT1 = HMSN1) or peroneal muscular atrophy is the most common example in clinical practice. It is an autosomal dominant disorder, mostly due to 1, 5 Mb duplication, involving the *PMP22* gene on chromosome 17p. It affects about 1/3000 and the age of awareness of the disorder ranges from childhood to middle age, although it is already established in childhood but is subclinical. Patients present with a chronic distal wasting of the lower limbs (Fig. 18.5) which progresses very slowly over many years. Typically there is marked wasting of the calf and distal thigh muscles with bilateral pes cavus (high arched feet with clawed toes), reflexes are lost as may be distal sensation. When wasting is severe the leg is said to resemble an inverted champagne bottle with a long neck. This may be accompanied by wasting of forearms and clawing of the hands in about a third of patients (Fig. 18.5). The level of disability is less than expected for the degree of wasting.

There is no specific treatment for inherited neuropathies. Nerve conduction studies show severe slowing of motor conduction velocities consistent with neuropathy. The differential diagnosis includes other long standing neuropathies including leprosy and less common forms of hereditary neuropathies. These rarer forms of hereditary neuropathies may be accompanied by signs of spastic paraparesis, deafness, optic atrophy and retinitis pigmentosa.



Characteristic wasting of the legs



Clawing of hands

Figure 18.5 Charcot-Marie-Tooth disease

HUNTINGTON'S DISEASE (HD)

This is an autosomal dominant inherited neurodegenerative disorder, affecting particularly the caudate nucleus and presenting in middle age with choreiform movements, progressive dementia and psychiatric symptoms. There is usually a positive family history. It affects about 1 in 10,000 persons and the causative gene lies on chromosome 4. It is an example of

a trinucleotide repeat disorder with affected patients always having more than 36 cytosine-adenosine-guanosine (CAG) repeats. The normal number of repeats is <30, intermediate is 30-35, HD with reduced penetrance 36-39, and >39 in HD. The length of the repeats predicts the onset of the disease, the greater the number of repeats the earlier the onset and vice versa. Juvenile HD, characterized by rigidity rather than the chorea, is almost invariably paternally inherited with repeat sizes of 60 or more. Early features of HD include psychiatric and behavioural problems, characteristic fidgetiness, chorea and loss of intellectual function. The symptoms typically start insidiously in middle age at around the 4th and 5th decade and progress relentlessly to death within 15-20 years.

The diagnosis can be confirmed by diagnostic genetic testing, if available. Concerned relatives at risk need to be counselled carefully before presymptomatic or predictive DNA testing is performed. There is no effective treatment but the chorea and the anxiety may respond to treatment early on in the disease. If the patient's chorea is symptomatic tetrabenazine can be effective but parkinsonism and depression are adverse effects. Benzodiazepines can be used for anxiety and low dose haloperidol (0.5 mg bd) for aggression.

OTHER HEREDITARY NEUROLOGICAL DISORDERS

Muscular disorders

The main inherited myopathies are the dystrophies, Duchenne's (DMD), Becker's (BMD), limb girdle (LGMD), facioscapulohumeral (FSHD) and myotonic dystrophy. These are presented in chapter 13.

HEREDITARY SPASTIC PARAPARESIS (HSP)

This is an uncommon form of hereditary spastic paraparesis that usually follows an inheritance pattern of autosomal dominance and less frequently recessive and X-linked. Several genetic mutations occur involving over 20 different loci on different chromosomes with the spasmin gene on chromosome 2p22 accounting for 40-50% of cases. Two main age groups are affected, the more common one <35 yrs and the other with later onset (40-60 yrs) although the onset can be at any age. The time course is usually one of slow progression over many years.

The most common clinical phenotype is usually that of a slowly progressive spastic paraparesis beginning in childhood or teens characterized by hyperreflexia and up going toes with increasing difficulty in walking. If it occurs in childhood there may be pes cavus or arched feet coupled with tightening of the calf muscles which may result in heel-toe walking. Bladder and bowel function are not usually directly affected. The upper limbs are variably affected. HSP can occur in conjunction with other neurological abnormalities. These include cerebellar, optic atrophy, peripheral neuropathy, ocular palsies, macular degeneration and retardation and dementia.

The differential diagnosis includes the main causes of chronic spastic paraparesis in Africa including cord compression, primary lateral sclerosis, Konzo and HTLV-1. Management is by genetic counselling and the paraplegia measures already outlined in chapter 10.

WILSON'S DISEASE

This is a rare autosomal recessive disorder of copper metabolism which affects mainly teenagers and young adults. It occurs with a frequency of between 1/50-100,000. It is characterized by the accumulation of copper in various organs of the body including the liver and brain. This is caused by a deficiency of caeruloplasmin a copper transporting protein in the blood. In the brain, it chiefly affects the basal ganglia resulting in a range of movement disorders including tremor, chorea, dystonia and parkinsonism. Diagnosis clinically is by finding evidence of cirrhosis in the liver or deposition of copper on the cornea called the Kayser-Fleisher ring. This may need a slit lamp examination. In the serum the caeruloplasmin level is low and copper level high. Treatment is with copper chelating drugs penicillamine and a low copper diet.

Key points

- hereditary neurological disorders are uncommon but cause serious long-term disability
- follow genetic principles of inheritance: autosomal dominance, recessive & X-linked inheritance
- often start in childhood or during teenage years & other family members are affected
- no effective treatment for most hereditary neurological disorders
- genetic counselling is very important

Selected references

- Ademiluyi SA, Ijaluola TG. *Neurofibromatosis in Nigerian children*. J Natl Med Assoc. 1988 Sep;80(9):1014-7.
- Amir H, Moshi E, Kitinya JN. *Neurofibromatosis and malignant schwannomas in Tanzania*. East Afr Med J. 1993 Oct;70(10):650-3.
- Bushby K, Finkel R, Birnkrant DJ, Case LE, Clemens PR, Cripe L, et al. *Diagnosis and management of Duchenne muscular dystrophy, part 1: diagnosis, and pharmacological and psychosocial management*. Lancet Neurol. 2010 Jan;9(1):77-93.
- Bushby K, Finkel R, Birnkrant DJ, Case LE, Clemens PR, Cripe L, et al. *Diagnosis and management of Duchenne muscular dystrophy, part 2: implementation of multidisciplinary care*. Lancet Neurol. 2010 Feb;9(2):177-89.
- Delatycki MB, Williamson R, Forrest SM. *Friedreich ataxia: an overview*. J Med Genet. 2000 Jan;37(1):1-8.
- Evans DG, Huson SM, Donnai D, Neary W, Blair V, Teare D, et al. *A genetic study of type 2 neurofibromatosis in the United Kingdom. I. Prevalence, mutation rate, fitness, and confirmation of maternal transmission effect on severity*. J Med Genet. 1992 Dec;29(12):841-6.
- Evans DG, Huson SM, Donnai D, Neary W, Blair V, Newton V, et al. *A genetic study of type 2 neurofibromatosis in the United Kingdom. II. Guidelines for genetic counselling*. J Med Genet. 1992 Dec;29(12):847-52.
- Goldman A, Krause A, Ramsay M, Jenkins T. *Founder effect and prevalence of myotonic dystrophy in South Africans: molecular studies*. Am J Hum Genet. 1996 Aug;59(2):445-52.
- Goldman A, Ramsay M, Jenkins T. *Ethnicity and myotonic dystrophy: a possible explanation for its absence in sub-Saharan Africa*. Ann Hum Genet. 1996 Jan;60(Pt 1):57-65.
- McGaughan JM, Harris DI, Donnai D, Teare D, MacLeod R, Westerbeek R, et al. *A clinical study of type 1 neurofibromatosis in north west England*. J Med Genet. 1999 Mar;36(3):197-203.
- Ramanjam V, Adnams C, Ndong A, Fieggen G, Fieggen K, Wilmshurst J. *Clinical phenotype of South African children with neurofibromatosis 1*. J Child Neurol. 2006 Jan;21(1):63-70.
- Pareyson D, Marchesi C. *Diagnosis, natural history, and management of Charcot-Marie-Tooth disease*. Lancet Neurol. 2009 Jul;8(7):654-67.

CHAPTER 18 INHERITED NEUROLOGICAL DISORDERS

- Roach ES, DiMario FJ, Kandt RS, Northrup H. *Tuberous Sclerosis Consensus Conference: recommendations for diagnostic evaluation. National Tuberous Sclerosis Association.* J Child Neurol. 1999 Jun;14(6):401-7.
- Roos RA. *Huntington's disease: a clinical review.* Orphanet J Rare Dis. 2010;5(1):40.
- Ginsberg Lionel, *Neurology, Lecture Notes*, Blackwell Publishing 8th edition 2005.
- Wilmshurst JM, Ouvrier R. *Hereditary peripheral neuropathies of childhood: an overview for clinicians.* Neuromuscul Disord. 2011 Nov;21(11):763-75.